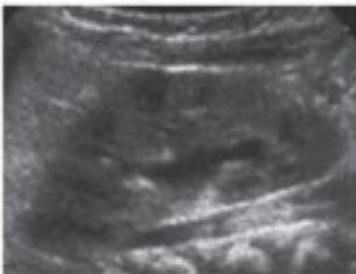
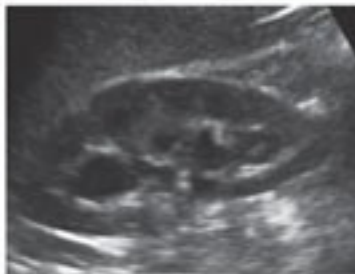

SFU grade 1



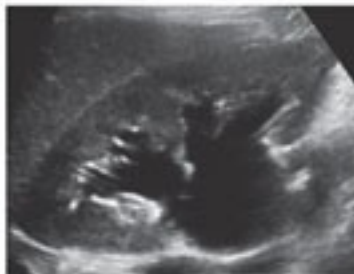Urine barely splits sinus

SFU grade 2



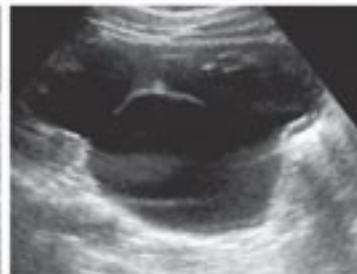Full pelvis, major calyces dilated

SFU grade 3



Uniformly dilated minor calyces, parenchyma spared

SFU grade 4



Parenchymal compromise