

# Pediatric Complete Abdominal Ultrasound

## **I. Patient Preparation**

- a. NPO 6-8 hours prior to the exam for adolescents and school-age children
- b. NPO for 4 hours prior to the exam for children under the age of 5.

## **II. Equipment**

- a. Performed with real-time scanner using a sector or curved linear transducer with frequencies ranging from 5.0 to 12 MHz, higher frequencies often necessary for children and infants. On occasion, large pediatric patients may require a lower frequency of 2.5 or 3.5 MHz.
- b. Linear transducer with and without standoff pad may be necessary for additional superficial areas of concern or superficial intraperitoneal pathology.
- c. Matrix x-plane and volumetric gray scale and/or power/color 3D evaluation can be employed.

## **III. Procedure Protocol**

- a. For **any** masses seen in any organ, use Power Doppler to assess for blood flow. All lesions should be demonstrated in gray scale with and without measurements, with imaging directed to evaluate the borders, echogenicity, size, mobility, through transmission, compressibility, vascularity as needed. Additional maneuvers such as Valsalva and compression should be employed if necessary.
- b. Different patient positions (e.g., supine, oblique, prone, decubitus, standing, sitting) should be documented if needed to evaluate for mobility of intraabdominal mass (i.e., exophytic uterine fibroid versus ovarian mass evaluation, fixed intraabdominal mass versus mobile intraabdominal mass) or to evaluate the abdominal wall (i.e., ventral abdominal hernia).
- c. If any area cannot be visualized due to bowel gas or surgical removal, etc., please note on image "region of" or "fossa"
  - i. Pancreas
    1. Image the pancreas in Sagittal and Transverse planes, taking images at the head, neck/uncinate process, body and tail or as much as can be seen.
    2. If the CBD can be seen at the head of the pancreas, take an AP measurement.
    3. Assess the peri-pancreatic region for any adenopathy, inflammation, pseudocyst or fluid. Image any abnormality.
    4. To overcome gas filled gastric antrum and duodenum, change of patient position (such as erect position), deep inspiration, distend the abdomen against the probe (ask the patient to push stomach out as if pregnant), and ingestion of water (2-3 glasses of water with scan in right semi-decubitus position; use of a drinking straw may decrease amount of swallowed air) may afford better visualization of the pancreas.
    5. The main pancreatic duct should measure approximately 2 mm in diameter or less.
    6. Although size varies with age and history, approximate normal AP measurements are 35 mm head, 10-15mm neck, 20 mm tail
  - ii. Aorta/Common Iliac Arteries
    1. Image the aorta in Sagittal and Transverse planes taking images at the proximal (posterior to the left lobe of the liver), mid (just distal to the SMA) and distal (just proximal to the umbilicus).
    2. Measure the aorta at all three levels when imaging in the Sagittal plane (AP measurement) and transverse plane (transverse measurement).

3. Image the common iliac arteries just below the bifurcation in the transverse plane with AP measurements.
4. Document any aortic dilatation in the Sagittal plane (maximum AP diameter and height) and in the Transverse plane (maximum transverse and AP measurement). Color Doppler or Power Doppler should be used to evaluate flow in the AAA. Angle corrected spectral analysis should also be used to evaluate the AAA.

iii. IVC

1. Image the IVC in the Sagittal plane as it courses through the liver. Color Doppler should be used to document flow/patency.
2. Vena cava filters, interruption devices, or catheters may need to be localized with respect to the hepatic and/or renal veins.

iv. Gallbladder

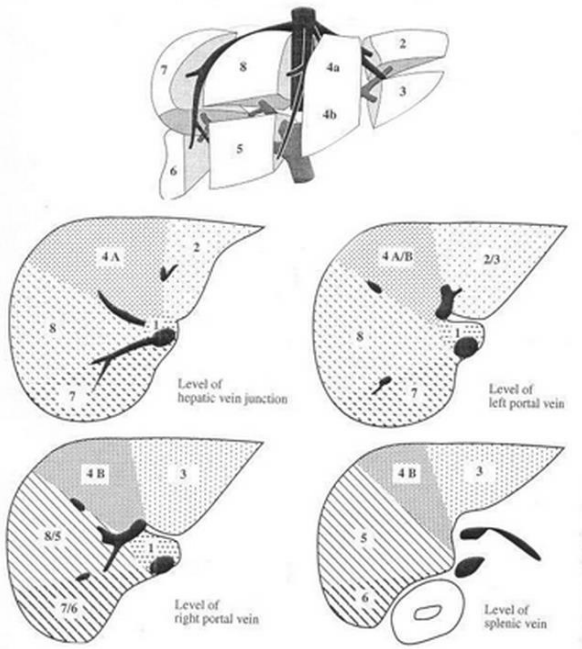
1. Image the gallbladder neck, body and fundus in the Sagittal and Transverse planes with the patient supine and left lateral decubitus positions. The gallbladder may also be evaluated with the patient sitting up. \*\*Note: You may image the parts of the GB in combination (ie. Neck/body or body/fundus together)
2. The gallbladder wall thickness should be measured in the Transverse plane using an AP measurement.
3. Assess for focal gallbladder tenderness (+Murphy's sign), gallstones, gallbladder sludge, and/or other masses such as polyps and document mobility.
4. Assess the area around the GB for any abnormality including pericholecystic fluid, inflammation and adenopathy.
5. Gallbladder wall thickness greater than 3 mm is thickened (normal  $\leq 3$ mm thickness).
6. Gallbladder length greater than 10 cm is dilated.
7. Reverberation artifact within the anterior wall can be minimized using a higher frequency probe or reducing transducer pressure.
8. Inspiration/expiration and/or abdomen distension (puff out stomach to distend abdomen) may improve visualization.

v. Biliary Tree

1. Image the bile duct anterior to the portal vein in the porta hepatis. Measure AP at the largest diameter (normal extrahepatic common duct AP diameter  $\leq 6$ mm). If the duct narrows after a dilation, measure both areas.
2. If duct is dilated, follow as far distal as possible. It may be necessary to turn patient to a LLD position. Evaluate for reason of dilation (pancreatic head mass, choledocholithiasis, etc.)
3. The intrahepatic and extrahepatic bile ducts should be evaluated for dilatation, wall thickening, intraluminal findings, pneumobilia, and other abnormalities.
4. Intrahepatic biliary dilatation present if intrahepatic bile duct diameter  $> 2$ mm.
5. The intrahepatic ducts can be evaluated by obtaining views of the liver demonstrating the right and left branches of the portal vein. Doppler may be used to differentiate hepatic arteries and portal veins from bile ducts. Intrahepatic bile ducts are better visualized on deep inspiration.
6. Oblique plane with patient in left decubitus position to minimize obscuration by overlying bowel gas to assess common hepatic/bile duct. Harmonic imaging allows better visualization of the dilated ductal wall and its content.

vi. Liver

1. Image the liver in the Sagittal (Longitudinal) and Transverse planes. Image the left lateral segment, left medial segment/caudate lobe, right anterior segment, right hepatic dome, right posterior segment/diaphragm, and right posterior segment/kidney in the longitudinal plane. Image the left lateral segment, left hepatic dome, left medial segment/caudate, right anterior segment/hepatic veins, right anterior segment/hepatic veins (with color), right hepatic dome in the transverse plane.
2. Assess the liver for echogenicity and size, using the right kidney for comparison. Measure the liver length using coronal right lobe ( $\geq 17$  cm is enlarged, although consider normal variant Riedel's lobe).
3. Evaluate the liver parenchyma for any focal or diffuse abnormalities.
4. Assess the major vessels of the liver, including the hepatic veins, main portal vein (see vii.), and, if possible, the left and right branches of the portal vein.
5. An attempt should be made to demonstrate the right hemidiaphragm and the adjacent pleural space.
6. Be prepared to change focal zone position and frequency of probe (or probes) to adequately assess both superficial and deep aspects



#### vii. Portal vein

1. Evaluate the main portal vein with color and pulsed Doppler (normal monophasic waveform). Assess for direction of flow (hepatopetal flow is normal).

#### viii. Kidneys

1. Image both kidneys in the Sagittal (Longitudinal) and Transverse planes, include the liver/right kidney and spleen/left kidney interfaces.
2. In the Transverse plane, the kidneys should be scanned sequentially from the upper (superior) to the lower (inferior) poles with images labeled appropriately.
3. Measure the kidney length (maximum elongated kidney at hilum) on the longitudinal image at the center, then obtain a longitudinal color doppler image. Obtain a color Doppler transverse mid pole image.

4. Assess the kidneys for any masses, hydronephrosis, calculi, or cysts. Assess the peri-renal areas for any abnormalities, such as perinephric fluid, mass, adenopathy. The cortices and renal pelves should be assessed.
5. If clinically suspected pyelonephritis, power Doppler evaluation on the longitudinal image of each kidney (or 3D color flow map) to document symmetric vascularity throughout the entire kidney.
6. In adults, asymmetric length of the kidneys greater than or equal to 1.5 cm is considered significant. In children, greater than or equal to 1 cm asymmetric length is significant.
7. If the ureter is dilated, it should be followed to evaluate for the cause and level of obstruction.
8. Decubitus, prone, or upright positioning may provide better images of the kidneys. When possible, renal echogenicity should be compared to the adjacent liver or spleen. If the kidneys are poorly visualized, narrowing the sector width and adjusting the depth should be performed to better assess the kidneys.
9. Use the liver for a window as much as possible to evaluate the right kidney. If bowel obscures the lower pole right kidney, left lateral decubitus position and/or deep inspiration should be performed to displace bowel for better imaging. Deep suspended inspiration should be performed if bowel obscures evaluation of the left kidney. If needed for better visualization, a posterior approach to evaluate the left kidney should also be performed (often as a last resort).

ix. Adrenal Glands

1. Normal adrenal glands are typically visualized in neonates. Normal adrenal glands are typically non-visualized in older childer, although should be evaluated in every patient with documentation of adrenal masses or thickened adrenal glands if identified (usually located superior to the right kidney, anterior to the upper pole left kidney).
2. In infants and neonates, image and measure in Sagittal and Transverse planes
3. Assess for masses, hemorrhage, calcification, or other abnormality.

x. Spleen

1. Image the spleen in the Sagittal and Transverse planes.
2. Measure the maximum length and width in the sagittal plane. Measure the height in the transverse plane.
3. Note any echogenic foci, perisplenic fluid, or masses
4. Doppler may be used to determine the presence and direction of flow in the splenic vein and artery.
5. An attempt should be made to demonstrate the left hemidiaphragm and the adjacent pleural space.
6. Calculation of Splenic Index.
  - a. The index is created by multiplying the three measurements (length, width, height) together – no division. Normal splenic index is 120-480cm (Reference: Computed Body Tomography with MRI Correlation by Joseph K.T. Lee, etal: page 976)
  - b. To measure the spleen accurately, in Sagittal: length and left to right width. Turn transducer 90 degrees and measure in transverse anterior to posterior, not from the patient's skin, but true anterior-posterior.

9. Right lateral decubitus position, inspiration/expiration, erect position, and/or abdomen distension (puff out stomach to distend abdomen) may improve visualization of the spleen.

xi. Bowel

1. The bowel may be evaluated for wall thickening, dilatation, muscular hypertrophy, masses, and other abnormalities. Color Doppler imaging may be done to assess blood flow.

**IV. Indications for ultrasound examination of the abdomen and/or retroperitoneum include, but are not limited to:**

1. Abdominal, flank, and/or back pain.
2. Signs or symptoms that may be referred from the abdominal and/or retroperitoneal regions such as jaundice or hematuria.
3. Palpable abnormalities such as an abdominal mass or organomegaly.
4. Abnormal laboratory values or abnormal findings on other imaging examinations suggestive of abdominal and/or retroperitoneal pathology.
5. Follow-up of known or suspected abnormalities in the abdomen and/or retroperitoneum.
6. Search for metastatic disease or occult primary neoplasm.
7. Evaluation of suspected congenital abnormalities.
8. Abdominal trauma.
9. Pretransplantation and post-transplantation evaluation.
10. Planning and guidance for an invasive procedure.
11. Search for the presence of free or loculated peritoneal and/or retroperitoneal fluid.

**V. Special circumstances**

1. Pediatric population typically assessed primarily with ultrasound. Imperative to assess regional structures on a regular basis to account for the patient's symptomatology. For example, if child presents with right lower quadrant pain, important to assess all the regional structures including the appendix, right ovary, urinary bladder, right colon, right lower quadrant lymph nodes, ileum, abdominal wall, right kidney, right ureter, gallbladder. Images are acquired according to standard protocol for study requested. If additional pathology is present, then those structures are also documented.