

General Information

I. Patient Preparation

- a. **Adolescents and adults:** The patient should drink 32 oz. of non-carbonated, clear liquid 1 hour prior to the exam time, finishing within 20 minutes. Patient should hold her bladder until instructed to empty by the technologist.
- b. **Children 5-12:** The patient should drink 16 oz. of non-carbonated, clear liquid 1 hour prior to the exam time, finishing within 20 minutes. Patient should hold her bladder until instructed to empty by the technologist.
- c. **Children under 5:** Patient should be instructed to attempt to hold her bladder until instructed to empty by the technologist.
- d. **Emergency Room Patients:** If possible, attempt to call and talk to ER staff caring for the patient to see if prep is possible. If case is too emergent, disregard the prep and proceed with exam as ordered by ER physician. Make full documentation of decision to not prep patient and who made the decision.

II. Equipment

- a. **Transabdominal:** All exams are to be performed with a real-time scanner using a curved array transducer with a frequency range of 1-5 MHz or higher for transabdominal examinations.
- b. **Transvaginal:** All exams are to be performed with a real-time scanner using a curved array transducer with a frequency range 4-8 MHz or higher. Matrix x-plane and volumetric gray scale and/or power/color 3D evaluation can be employed. 3D image(s) of the endometrium should be obtained using 3D sweep with reconstruction, if equipment available.

III. Procedure Protocol

a. Transabdominal Exam

1. Sagittal imaging of the uterus starting ML and imaging through the right and left sides (labeled accordingly) with length and AP measurements at the ML level of uterus. Images should be able to fully assess myometrial echotexture. *(minimum 3 grayscale images. Images with and without calipers represent 1 image)*
2. Sagittal image of the cervix.
3. Sagittal endometrium with and without AP thickness measurement.

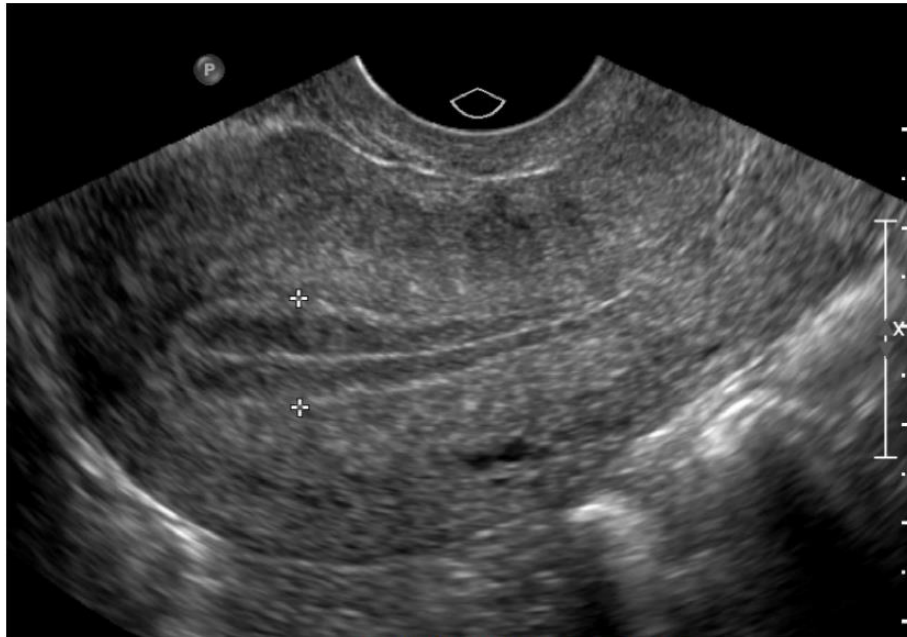

Figure 1. Measurement of endometrial thickness.
The endometrial thickness measured in its thickest portion from echogenic to echogenic border (calipers) perpendicular to the midline longitudinal plane of the uterus.

4. Sagittal and transverse imaging of both right and left adnexa with and without color Doppler showing the iliac arteries as the lateral boundary of the adnexa.
5. Transverse imaging of the uterus from inferior (vaginal canal) to superior (fundus) (labeled accordingly), with a width measurement at mid body of uterus at widest plane. *(minimum 3 greyscale images. Images with and without calipers represent 1 image)*
6. Sagittal imaging of the right and left ovaries. The length and AP measurements are taken at plane of longest sagittal portion of the ovary. Images should be able to fully assess ovarian echotexture. Image the ovary at the lateral, mid and medial portions and label appropriately. *(minimum 3 greyscale images of each ovary. Images with and without calipers represent 1 image)*
7. Transverse imaging of the right and left ovaries. The width measurement is taken at the widest transverse plane of the ovary. Images should be able to fully assess ovarian echotexture. Image the ovary at the superior, mid and inferior portions and label appropriately. *(minimum 3 greyscale images of each ovary. Images with and without calipers represent 1 image)*
8. Color and/or Power Doppler **AND** Pulsed Doppler including spectral tracing of one each intra-ovarian vein and artery for each ovary. The ovary cannot be labeled as “normal” without the proper documentation of pulsed doppler flow within the cortex of each ovary.
9. Assess the urinary bladder for wall thickening, debris. Assess for pelvic masses and bowel pathology. Assess for pelvic free fluid.
10. For any masses seen in any organ, use Power Doppler to assess for blood flow. All lesions should be demonstrated in gray scale with and without measurements and appropriate labeling. Additional maneuvers such as compression should be employed if necessary.

11. Different patient positions (e.g., supine, oblique, prone, decubitus, standing, sitting) should be documented if needed to evaluate for mobility of intra-abdominal mass (i.e., exophytic uterine fibroid versus ovarian mass evaluation, fixed intra-abdominal mass versus mobile intra-abdominal mass).

b. **Transvaginal Exam**

1. The patient is instructed to empty bladder fully prior to performing transvaginal imaging. If there is uncertainty of the bladder emptying completely, the technologist should look again transabdominally to see if patient should void again. *For best imaging, the bladder should be as empty as possible!
2. The sequence of images should be the same as the transabdominal steps listed above. If any structure or area cannot be visualized due to bowel gas or surgical removal, etc., please note on image "region of" or "adnexa".
3. Additional maneuvers such as pressure with transvaginal probe to determine whether an adnexal mass is ovarian or paraovarian should be employed if needed.
4. When maneuvering the probe to visualize the adnexa, withdraw slightly then angle the probe against the fornix to minimize patient discomfort against the cervix.
5. Elevate the patient's bottom on a thick sponge/pillow to assist with the scan.

IV. **Policies**

- a. **Transvaginal Exam:** The patient must be properly informed of the transvaginal procedure before beginning, with a clear verbal authorization.
 - i. **Non-sexually active patient:**
 1. **Under 18:** Transvaginal imaging should not be utilized. If it is deemed necessary by the ordering physician and indicated so on the order, the legal custodian must be informed of the procedure and give a verbal consent prior to the onset of the exam. This should be well documented by the technologist and radiologist in the report. If needed, consider translabial sonographic evaluation.
 2. **Over 18:** Transvaginal imaging should be utilized only if ordered on the script by the physician. The patient should be informed of the procedure and given a verbal consent prior to the onset of the exam. If needed, consider translabial sonographic evaluation.
 3. **Helpful Questions**
 - a. Have you had an internal exam and/or PAP smear by your gynecologist?
 - b. Do you use tampons?
 - c. Would you like to see the transducer before deciding?
 4. **Helpful advice**
 - a. Show the TV probe and explain the procedure including length of insertion (which is approximately the same as a tampon),

explain importance of TV imaging which is considered the gold standard of imaging due to superior accuracy and diagnostic resolution.

- b. Offer for the patient to guide the probe in far enough to see the fundus, especially if you encounter some resistance during insertion of the probe.

ii. **Sexually active patient:**

1. **Under 18:** Transvaginal imaging should be utilized in conjunction with transabdominal imaging if indicated on the physician order. The patient and legal custodian must be informed of the procedure and give a verbal consent prior to the onset of the exam.
2. **Over 18:** Transvaginal imaging should be utilized if indicated on the physician order, unless the patient declines the TV exam, there is a medical contraindication to a TV scan, or the ordering physician requests ONLY a TA scan. All patients should be informed of the procedure and give a verbal consent prior to the onset of the exam.

- iii. **Non-consenting patient:** Any patient who is over 18 with a guardian who is a medical power of attorney should be addressed in the same manner as a patient under the age of 18.

V. Special circumstances

a. Ovarian follicle assessment

- i. Perform routine non-obstetric pelvic ultrasound as outlined above. In addition, need to document the following:
 1. Ovarian volume
 2. Number of follicles in each ovary
 3. Need to measure each follicle over 1 cm in size
 4. Adequate visualization of the endometrial echo complex to evaluate for multilayered appearance. Document if trilaminar or homogeneous.
- ii. Ultrasound can be used for Clomid follicle tracking and/or determination of when to proceed or cancel therapy (for example, if too many large follicles are noted); or decision to increase dosage of Clomid (for example, if no dominant follicle is seen). The successful use of Clomid requires monitoring of induced cycles. If carefully monitored cycles indicate ovulation, the patient is instructed to use the same dosage of medication in her upcoming cycle.
- iii. The following ultrasound scans are used to monitor induced cycles:
 1. Baseline ultrasound (CD 2-5) to rule out residual follicles > 15 mm
 2. Follicular monitoring with ultrasound and serum E2 levels (start 4-6 days after last pill)
- iv. If pregnancy does not occur after six monitored normal Clomid cycles, ultrasound is performed to exclude luteinized unruptured follicle syndrome scheduled on CD 12 to 14.

- v. Depict developing follicles, beginning at the time they measure between 3 and 5 mm. As follicles spontaneously reach maturity in the natural cycle their inner dimensions range from 17 to 25 mm
- vi. Sonographic delineation of follicle size is crucial because hCG is best administered once follicles reach 15 to 18 mm in size even in non-IVF cycles when ovulation is allowed to occur, as the LH surge is less frequent when hMG is used for stimulation. For IVF, follicles are typically aspirated when they reach 15 to 18 mm in average diameter and when the E2 level is approximately 400 pg/ml per large follicle (20). Another sonographic sign of mature follicles is the presence of low-level intrafollicular echoes, as mentioned earlier. When follicles >15 mm are aspirated, oocytes are at all stages of maturity. Therefore, one can rely on follicular diameters alone if the patient's previous cycles and her E2 response are known
- vii. Serum E2 level on the day of hCG injection can be predicted: $E2 = 291 \text{ pg/ml} + 180(x) + 64(y) + 18.7(z)$ where x, y and z represent follicles measuring >17 mm, 15 to 16 mm and <14 mm respectively. Whereas the sonographic finding of enlarged ovaries with multiple immature follicles may suggest the possibility of hyperstimulation, extremely high levels of E2 (over 3000 pg/ml) can be a more accurate predictor of this syndrome. On sonography, patients with ovarian hyperstimulation syndrome (OHSS) usually have enlarged ovaries (over 10 cm) that may contain several hypoechoic areas. The hypoechoic areas may correspond to atretic follicles, or to regions of hemorrhage within the ovary.
- viii. Endometrium: In the late proliferative or periovulatory phase of endometrial development, a multilayered endometrium can be distinguished. The inner hypoechoic area probably represents edema in the compact layer of the endometrium. The endometrium would have the configuration of a theta with respect to the hypoechoic area as imaged in the semi-axial or semi-coronal plane. Patients who achieve pregnancy more frequently have a multilayered periovulatory endometrium than those in the group who do not conceive. In the secretory phase, the thickness of the endometrium increases to between 8 and 16 mm and is echoic, probably due to the increased mucus and glycogen within the glands.
- ix. Endometrium late proliferative phase. Grade I was characterized by homogenous echogenicity of the endometrium, while grade II was characterized by an outer peripheral layer of dense echogenicity surrounding a central sonolucent area (halo pattern). Grades I and II were subclassified into group A (>9 mm thick) and group B (<9 mm). Grade IIA was optimal, as it was associated with a clinical pregnancy rate per embryo transfer of 33% while the other three groups were poor as they were associated with a rate of 7% only. Women aged 41-45 years experienced a 25% incidence of poor sonographic grades compared to only 5% incidence in women <40 years.

Total number of antral follicles	Expected response to injectable stimulating drugs and chances for IVF success
Less than 4	Extremely low count, very poor (or no) response to stimulation. Cycle cancellation is likely. Should consider not attempting IVF at all.
4-6	Low count, we are concerned about a possible/probable poor response to the stimulation drugs. Likely to need high doses of FSH product to stimulate ovaries adequately. Higher than average rate of IVF cycle cancellation . Lower than average pregnancy rates for those cases that make it to egg retrieval.
7-10	Reduced count. Higher than average rate of IVF cycle cancellation. Moderately reduced chances for pregnancy success as a group.
11-15	Intermediate count. Response to drug stimulation is sometimes low, but usually adequate. Slightly increased risk for IVF cycle cancellation. Pregnancy rates as a group are slightly reduced compared to the "best" group.
16-30	Normal (good) antral count, should have an excellent response to ovarian stimulation. Likely to respond well to low doses of FSH drugs. Very low risk for IVF cycle cancellation. Some risk for ovarian overstimulation. Very good pregnancy success rates overall.
Over 30	High count, watch for polycystic ovary type of ovarian response. Likely to have a high response to low doses of FSH product. Higher risk for overstimulation and ovarian hyperstimulation syndrome . Very good pregnancy rate overall.

b. Polycystic ovaries syndrome

- i. Key clinical features include menstrual cycle disturbance, hyperandrogenism and obesity.
- ii. Criteria to define polycystic ovaries (PCO) should have at least one of the following: either 12 or more follicles measuring 2 to 9 mm in diameter (on a single image) or increased ovarian volume (>10 cm³). If there is a follicle ≥ 10 mm in diameter or a corpus luteum, the scan should be repeated at a time of ovarian quiescence (the next cycle) in order to calculate volume and area. The presence of a single PCO is sufficient to provide the diagnosis. The distribution of follicles and a description of the stroma are not required in the diagnosis. Increased stromal echogenicity and/or stromal volume are specific to PCO, but it has been shown that the measurement of ovarian volume (or area) is a good surrogate for quantification of the stroma in clinical practice.
- iii. Whenever possible, the transvaginal approach should be preferred, particularly in obese patients (*must be ordered on script by physician*). Regularly menstruating women should be scanned in the early follicular phase (days 3 to 5). Oligo-/amenorrhoeic women should be scanned either at random or between days 3 to 5 after a progestogen-induced bleed.
- iv. Calculation of ovarian volume is performed using the simplified formula for a prolate ellipsoid (0.5 x length x width x thickness).
- v. Follicle number should be estimated both in longitudinal, transverse and antero-posterior cross sections of the ovaries. Follicle size should be expressed as the mean of the diameters measured in the three sections.
- vi. Normal stromal echogenicity is said to be less than that of the myometrium.

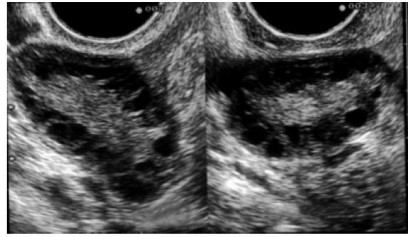


Figure 1. Polycystic ovaries (B mode, transvaginal route). In both left and right ovaries, the ovarian length and width are increased as well as the ovarian area. The follicle number, with a diameter mainly between 2 and 5 mm, is more than 12. The distribution within the ovaries is mainly peripheral. The increased and hyperechoic stroma occupies the centre of the ovaries.

<https://www.acr.org/-/media/ACR/Files/Practice-Parameters/US-Pelvis.pdf>