

Updated Fleischner Society Guidelines for Managing Incidental Pulmonary Nodules: Common Questions and Challenging Scenarios

Juliana Bueno, MD
Luis Landeras, MD
Jonathan H. Chung, MD

Abbreviation: GGN = ground-glass nodule

RadioGraphics 2018; 38:1337–1350

<https://doi.org/10.1148/rg.2018180017>

Content Codes: **CH** **CT** **OI**

From the Department of Radiology and Medical Imaging, University of Virginia Medical Center, 1215 Lee St, PO Box 800170, Charlottesville, VA 22908 (J.B.); and Department of Radiology, University of Chicago, Chicago, Ill (L.L., J.H.C.). Presented as an education exhibit at the 2017 RSNA Annual Meeting. Received February 15, 2018; revision requested March 20 and received April 13; accepted April 26. For this journal-based SA-CME activity, the authors, editor, and reviewers have disclosed no relevant relationships. **Address correspondence** to J.B. (e-mail: jmb3dt@virginia.edu).

See discussion on this article by Leung (pp 1350–1351).

©RSNA, 2018

SA-CME LEARNING OBJECTIVES

After completing this journal-based SA-CME activity, participants will be able to:

- Describe the most recent relevant modifications to the Fleischner Society guidelines for managing solid incidental pulmonary nodules.
- Apply appropriate actions to specific situations that may represent challenges in the decision-making process when the revised Fleischner Society criteria are used.
- Use the updated Fleischner Society criteria for managing incidental nodules with a better understanding of the reasons behind the recent modifications.

See rsna.org/learning-center-rg.

The new guidelines for managing incidental pulmonary nodules published by the Fleischner Society in 2017 reflect an improved understanding of the risk factors and biologic features of lung cancer. Specific topics emphasized in the updated guidelines include a new threshold size for follow-up, the importance of the morphologic features of nodules, accurate nodule measurements, recognition of subsolid components, understanding interval growth or change in nodule morphology, and knowledge of patient risk factors. The updated guidelines enable greater personal flexibility in the decision-making process and encourage individualized management of pulmonary nodules. These factors may introduce new challenges for radiologists, who previously used solely nodule size to make management recommendations. The authors describe eight scenarios that illustrate the challenges potentially encountered when applying the new guidelines to pulmonary nodule management.

©RSNA, 2018 • radiographics.rsna.org

Introduction

In 2005, the Fleischner Society released guidelines for the management of pulmonary nodules detected incidentally at CT examinations performed for purposes other than lung cancer screening (1,2). Since then, these guidelines have been widely adopted for the management of incidentally detected pulmonary nodules, being among the most frequently cited recommendations in the field of radiology (3). The main purpose of the Fleischner Society guidelines is to decrease the number of unnecessary follow-up examinations performed (4). Despite widespread awareness of guidelines for pulmonary nodule management, including those proposed by the Fleischner Society (4) and the American College of Chest Physicians (5), adherence to the recommendations has not been consistent. Guideline compliance has been reported to be as low as 34% among radiologists (3,6), including thoracic radiologists, who reportedly have low adherence to the Fleischner Society guidelines (7). Pulmonologist adherence to the nodule management guidelines proposed by the American College of Chest Physicians also is low, with inconsistent follow-up decisions regarding selection of the next management step reported in more than 60% of cases in one study (8).

The factors that influence radiologists' adherence to guidelines for pulmonary nodule management have been studied previously (6). The size of the nodule, type of imaging modality depicting the nodule (ie, chest versus abdominal CT), and subspecialty of the radiologist interpreting the imaging results are the main variables that influence guideline adherence (3,6,9). The Fleischner Society guidelines for nodule management released in 2017 (4) are more comprehensive and inclusive and are based on a better

TEACHING POINTS

- The use of thin (1.0–1.5-mm) sections is essential for the characterization of solid and subsolid pulmonary nodules and the detection of calcium or fat components; these features can lead to different management options.
- The size and morphology of a pulmonary nodule are the two primary determinants of cancer risk. Morphology refers specifically to the margins (smooth, lobulated, or spiculated) and attenuation (solid, partly solid, or purely ground glass) of the nodule.
- Older age, heavy smoking, larger nodule size, upper lobe location, and/or nodule margin irregularity or spiculation increases the risk of cancer.
- If a nodule adjacent to the pleura or a fissure demonstrates a round morphology or contour irregularity and/or the adjacent fissure is abnormal (ie, retracted, bowed, or transgressed), follow-up CT at 6–12 months is indicated.
- The suspicious features observed in cystic airspaces associated with primary lung cancer are new microcysts in a solid or subsolid nodule, or an endophytic mural nodule, exophytic mural nodule, and/or progressive or asymmetric wall thickening of a preexisting cystic lesion.

understanding of the morphologic features of pulmonary nodules, reliable size measurements, the recognition of subsolid components, an understanding of interval growth or change in nodule morphology, and knowledge of patient risk factors (4). Aimed at expanding the flexibility of ordering clinicians and individualizing the management of nodules, the new criteria demand a better understanding and knowledge of pulmonary nodules and the factors that influence their behavior over time. These mandates may introduce new challenges for radiologists and perpetuate the low adherence to management guidelines.

There are three common questions pertaining to nodule management in clinical practice. These questions are specifically related to (a) the patient population to which the guidelines apply, (b) the technical considerations pertaining to the follow-up CT examinations, and (c) the integration of risk factors into the decision management process. We address these considerations and describe eight clinical scenarios that illustrate the challenges potentially encountered when applying the updated Fleischner Society guidelines for nodule management. The rationales underlying the recommendations and the strategy for addressing each clinical scenario are discussed.

Key Changes in the 2017 Updated Guidelines

Important limitations of the original Fleischner Society guidelines published in 2005 (1), mainly the lack of consideration of subsolid and multiple solid nodules in the management algorithm, were

recognized (10). Interim and official guidelines for the assessment of subsolid lesions were published in 2009 and 2013, respectively (11,12). Specific recommendations for the management of multiple solid pulmonary nodules were not available until recently.

New data obtained from lung cancer screening trials have led to an improved understanding of the natural course, imaging appearance, pathologic correlation, and behavior of malignant and benign pulmonary nodules (13,14). The updated information helps to address the known limitations of the original recommendations; these restrictions are now reflected in the current guidelines (4).

The latest version of the Fleischner Society guidelines for incidental nodule management includes a number of important modifications. Specifically, the minimal threshold size for follow-up of solid nodules has been increased, and the recommended follow-up is expressed as a range of time rather than a specific interval for follow-up. This latter modification is an attempt to allow health care providers (ie, radiologists and ordering clinicians) more flexibility in nodule management. In addition, patient risk factors and preferences affect the management of pulmonary nodules (5) and are addressed in the new recommendations. The guidelines for solid and subsolid nodules are summarized in the Table (4). Recommendations for the management of multiple solid pulmonary nodules, which was not addressed previously, also are included in the Table.

Clarifying Doubts regarding Solid and Subsolid Pulmonary Nodule Measurements

Accurate measurements are crucial to the management and decision-making processes in cases of pulmonary nodules, as they enable estimation of baseline risk, appropriate assignment of patients in the management algorithm, and optimized follow-up of lesion growth at subsequently performed examinations (4,15). The assessment of pulmonary nodules begins with the differentiation between a solid lesion and a subsolid lesion, which is based on use of the appropriate technique. Given the importance of accurate measurements for risk estimation, the Fleischner Society released a comprehensive article outlining its recommendations for measuring pulmonary nodules at CT (15).

Measurements should be performed on high-spatial-frequency (sharp) filter, reconstructed thin-section CT images displayed in lung windows, usually in the axial plane. If the maximal nodule dimensions are visible in the coronal and/

2017 Fleischner Society Guidelines for Management of Incidentally Detected Pulmonary Nodules

A: Solid Nodules*

Nodule Type	Nodules <6 mm (<100 mm ³)	Nodules 6–8 mm (100–250 mm ³)	Nodules >8 mm (>250 mm ³)	Comments
Single				
Low risk	No routine follow-up	CT at 6–12 mo, then consider CT at 18–24 mo	Consider CT at 3 mo, PET/CT, or tissue sampling	Nodules <6 mm do not require routine follow-up in low-risk patients (recommendation 1A)
High risk	Optional CT at 12 mo	CT at 6–12 mo, then at 18–24 mo	Consider CT at 3 mo, PET/CT, or tissue sampling	Certain patients at high risk with suspicious nodule morphology, upper lobe location, or both may warrant 12-mo follow-up (recommendation 1A)
Multiple				
Low risk	No routine follow-up	CT at 3–6 mo, then consider CT at 18–24 mo	CT at 3–6 mo, then consider CT at 18–24 mo	Use most suspicious nodule as guide to management; follow-up intervals may vary according to size and risk (recommendation 2A)
High risk	Optional CT at 12 mo	CT at 3–6 mo, then at 18–24 mo	CT at 3–6 mo, then at 18–24 mo	Use most suspicious nodule as guide to management; follow-up intervals may vary according to size and risk (recommendation 2A)

B: Subsolid Nodules*

Nodule Type	Nodules <6 mm (<100 mm ³)	Nodules ≥6 mm (≥100 mm ³)	Comments
Single			
Ground glass	No routine follow-up	CT at 6–12 mo to confirm persistence, then CT every 2 y until 5 y	For certain suspicious nodules <6 mm, consider follow-up at 2 y and 4 y; if solid component(s) develops or growth occurs, consider resection (recommendations 3A and 4A)
Partly solid	No routine follow-up	CT at 3–6 mo to confirm persistence; if lesion is unchanged and solid component remains <6 mm, annual CT should be performed for 5 y	In practice, partly solid nodules cannot be defined as such until they are ≥6 mm, and nodules <6 mm usually do not require follow-up; persistent partly solid nodules with a solid component ≥6 mm should be considered highly suspicious (recommendations 4A–4C)
Multiple	CT at 3–6 mo; if lesion is stable, consider CT at 2 y and 4 y	CT at 3–6 mo; subsequent management based on the most suspicious nodule(s)	Multiple <6-mm pure GGNs [†] usually are benign, but consider follow-up at 2 y and 4 y in select patients at high risk (recommendation 5A)

Note.—Adapted and reprinted, with permission, from reference 4. These recommendations do not apply to lung cancer screening, patients with immunosuppression, or patients with a known primary cancer.

*Dimensions are the average of long and short axes, rounded to the nearest millimeter.

[†]GGNs = ground-glass nodules.

or sagittal plane, the measurements should be obtained on these images. Measurements should be expressed to the nearest whole millimeter (15). To estimate risk and use the guidelines, obtaining an average of the maximal long-axis and perpendicular maximal short-axis dimension measurements in the same plane is recommended

for solid and partly solid nodules smaller than 10 mm. For larger solid and partly solid nodules, recording both the long-axis measurement and the short-axis measurement is recommended. For all partly solid nodules with a solid component larger than 3 mm, the maximal diameter of the solid component also should be measured and

reported (12,15). We encourage readers to refer to the official publication (15) for additional important considerations.

Questions Commonly Asked in Clinical Practice

Pulmonary nodules are common and most frequently detected incidentally. Prevalences of between 25% and 51% in healthy adult volunteers and lung cancer screening populations have been demonstrated in large studies (5,16), with almost one-fourth of these individuals found to have one to six nodules at low-radiation-dose chest CT (5,16). The main management-related dilemma for radiologists and clinicians stems from the high prevalence of nodules but low likelihood of cancer for most of them (5). This factor creates a challenge in terms of the decision-making process and discussions with patients (17). The assessment of pulmonary nodules is based on meticulous and optimal evaluation of the nodules. Adherence to some basic but important primary requirements is essential for appropriate risk estimation and subsequent appropriate management.

Question 1

It is important to understand the patient population(s) for which the Fleischner Society guidelines are intended. Are these guidelines intended for the management of nodules found incidentally in *any* patient?

No. The guidelines are recommended for the management of nodules found incidentally in patients older than 35 years, with the exclusion of specific high-risk groups. With specific conditions and risk factors considered, the patient groups described in the following sections are excluded from these recommendations, and the decision-making process for these cohorts should be individualized.

Patients Aged 35 Years or Younger.—The risk of cancer varies during a person's life span. The lifetime risk of receiving a diagnosis of cancer by age 30 years is approximately 1% and is 2% by age 40 years (18,19). Consequently, individuals aged 35 years or younger are considered to have a low risk for malignancy, and the management of incidentally found pulmonary nodules in this group should be individualized. In these individuals, the likelihood of infectious pulmonary nodules is much higher than the likelihood of cancer. Thus, routine follow-up of small (<6-mm) incidentally found nodules typically is not indicated.

Patients with Known Malignancy.—The lungs are the most common site of metastasis of solid

tumors (20). The prevalence of pulmonary metastasis in individuals with extrapulmonary malignancies is reportedly as high as 54% (21,22). In a patient with known malignancy, the likelihood of an incidentally detected pulmonary nodule being cancer is higher than that in the general population. Hence, the treatment for this group of patients should be individualized according to the specific risk factors and biologic behavior of the tumor. The imaging and clinical workup is intended to rule out or confirm the possibility of pulmonary metastasis, with shorter imaging follow-up intervals and invasive procedures placed higher in the management algorithm (23,24).

Immunocompromised Patients.—Regardless of the underlying cause of immunosuppression, this group is at higher risk for opportunistic pulmonary infections, which comprise approximately 75% of all infectious complications in this population (25). CT has an important role in the diagnosis of opportunistic infections in immunocompromised patients, mainly in the detection of subtle patterns of disease that may lead to the manifestation of specific microorganisms known to progress with an aggressive and sometimes fatal course in this population (26).

Lung Cancer Screening Population.—Predominantly on the basis of the National Lung Screening Trial findings, the U.S. Preventive Services Task Force (27) recommends lung cancer screening with low-dose chest CT for eligible high-risk current and former smokers. The criteria for imaging follow-up and management in this group of patients are specifically dictated by the Lung CT Screening Reporting and Data System (28), a quality assurance tool designed by the American College of Radiology to standardize the reporting and management of nodules in this population. Because patients in screening programs return for annual screening in 12 months, even when their screening results are negative, and owing to their high risk status and relative absence of comorbidity, patients in lung cancer screening programs are managed differently from patients with incidentally discovered nodules. Thus, patients in lung cancer screening programs are excluded from the guidelines for incidental nodule management proposed by the Fleischner Society (4).

Question 2

A pulmonary nodule is found incidentally at CT performed with 5-mm-thick sections. Are there any technical specifications for the follow-up examination?

Yes. The latest version of the Fleischner Society guidelines outlines the technical parameters

required to accurately measure and characterize pulmonary nodules. Similarly, it addresses nodules found on incomplete CT scans (ie, obtained without a specified section thickness) and on scans obtained with thick (>2-mm) sections. Although the guidelines do not specifically recommend a time frame for follow-up of incidental nodules found on thick-section scans (either complete chest CT or incomplete lung CT), this scenario is commonly encountered in clinical practice.

The use of thick sections increases volume averaging and limits the characterization of pulmonary nodules. The use of thin (1.0–1.5-mm) sections is essential for the characterization of solid and subsolid pulmonary nodules and the detection of calcium or fat components; these features can lead to different management options. For this reason, the new guidelines specify that all thoracic CT scans in adults should be acquired with contiguous thin sections.

If the examination at which the nodule is detected is performed with sections thicker than 2 mm, regardless of whether it is dedicated chest CT or incomplete CT of the lung (such as neck or abdominal CT), the acquisition of short-term follow-up complete chest CT scans with thin (≤ 1.5 -mm) sections should be considered for a baseline comparison (4). For this specific scenario, in which a nodule is found on a thick-section scan, there are no specific recommendations in the updated guidelines as to when to perform the follow-up examination or further characterize the nodule. It could be inferred, on the basis of the malignancy risk, that for small (<6-mm) nodules, no follow-up is necessary. However, for larger (≥ 6 -mm) nodules, complete thin-section CT of the chest is indicated as early as possible to determine subsequent management.

For nodules found at incomplete CT, the new guidelines propose that typically no follow-up is necessary if the lesion is smaller than 6 mm. For lesions measuring 6–8 mm, the follow-up with complete chest CT should be determined according to the patient's individual risk factors and performed in 3–12-month intervals. For nodules larger than 8 mm or with very suspicious features, further characterization with complete thoracic CT should be performed as early as possible (4).

Question 3

The guidelines emphasize the use of individual risk factors in the decision management process. Which risk factors can be used to determine management?

The Fleischner Society guidelines for nodule management are based on individual risk estima-

tion. The size and morphology of a pulmonary nodule are the two primary determinants of cancer risk (13). Morphology refers specifically to the margins (smooth, lobulated, or spiculated) and attenuation (solid, partly solid, or purely ground glass) of the nodule. The clinical risk factors for lung cancer are numerous and include smoking, exposure to other carcinogens, emphysema, nodule location, and family history of lung cancer. These risk factors have variable influence on the likelihood of cancer in individual patients. Although several models for predicting lung cancer have been developed and proven to be useful for risk estimation in large lung cancer screening trials (13,14), in the latest version of the Fleischner Society guidelines, use of the categories proposed by the American College of Chest Physicians is recommended. The American College of Chest Physicians defines three risk categories: low, indicating a less than 5% estimated risk of cancer; intermediate, a 5%–65% estimated risk; and high, a greater than 65% estimated risk (5). Older age, heavy smoking, larger nodule size, upper lobe location, and/or nodule margin irregularity or spiculation increases the risk of cancer (4,5).

Challenging Scenarios

In the latest update of the Fleischner Society guidelines, the recommendations for managing single and multiple, solid and subsolid pulmonary nodules are compiled according to size and risk factor in a comprehensive table (Table) (4). To promote individualized management and flexibility of the health care provider during the decision-making process and incorporate patient preferences, specific time frames for follow-up have been replaced with ranges of times for the next appropriate follow-up step. The Table also includes specific comments and explanations regarding some of these recommendations. The addition of terms such as *optional* and *consider* are intended to promote flexibility and autonomy in decision making, but it leaves room for uncertainty regarding the next best step in specific cases.

Scenario 1

For a solid pulmonary nodule smaller than 6 mm in a high-risk patient, “optional CT at 12 months” is recommended in the guidelines. Specifically when is this optional follow-up indicated?

The minimal threshold size for follow-up of a pulmonary nodule is based on a cancer risk estimate of at least 1% (4). Analysis of data from the NELSON (Nederlands-Leuven Longkanker Screenings Onderzoek [Dutch-Belgian Lung Cancer Screening Trial]) trial (14) revealed that nodules smaller than 5 mm or with a volume of less than 100 mm³ are not predictive of lung

cancer. On the basis of this cancer risk statistic (13,14), less than 6 mm (ie, 5 mm or smaller) is the defined cutoff size for follow-up, even in high-risk patients, in the updated Fleischner Society guidelines. Data from lung cancer screening trials have indicated that an upper lobe location and/or suspicious morphology (such as subsolid density, or contour irregularity or spiculation) of a nodule smaller than 6 mm increases the risk of cancer to 1%–5% (4). Thus, for a solid nodule that is slightly smaller than 6 mm but located in the upper lobes and/or has contour irregularity or spiculation, follow-up chest CT at 12 months may be required. Within certain limits, lesion morphology can trump size as a feature suspicious for cancer (Fig 1).

Scenario 2

The recommendation for management of single solid 6–8-mm nodules in low-risk patients is to perform follow-up CT at 6–12 months and then consider performing CT at 18–24 months. Is nodule stability at 6 months reassuring enough to discontinue follow-up?

The recommendation of CT follow-up at 6–12 months for single solid 6–8-mm nodules depends on the nodule morphology and the patient's preferences (grade C recommendation: strong recommendation, low-quality or very-low-quality evidence) (4). Analysis of data from the NELSON lung cancer screening trial (14) revealed an intermediate probability of cancer for nodules 5–10 mm in diameter (mean probability, 1.3%; 95% confidence interval [CI]: 1.0%, 1.8%) or 100–300 mm³ in volume (mean probability, 2.4%; 95% CI: 1.7%, 3.5%). In addition, these trial results support assessment of the volume doubling time of nodules in this size range, which had higher sensitivity (mean, 92.4%; 95% CI: 83.1%, 97.1%) and specificity (mean, 90.0%; 95% CI: 89.3%, 90.7%) (14).

The definition of significant growth of a lesion between examinations is essential, especially for small lesions, for which the interobserver variability of measurements is higher (29). The association between probability of cancer and volume doubling time has been well established, with the volume doubling times for most cancers ranging from 100 to 400 days (14). An increase in the volume of a lesion translates into an increase in lesion diameter. A 26% increase in lesion diameter corresponds to a doubling in the volume of the lesion (assuming a spherical geometry and consistent growth rate), and the accuracy of growth assessments is higher with increasing intervals between examinations (15,30).

After the 2017 updated guidelines were released, a 2-mm threshold for growth was pro-

posed in a statement from the Fleischner Society, clarifying the recommendations for measuring pulmonary nodules at CT (15). This threshold has been adopted by other international organizations (30). To determine the appropriate interval for follow-up and have reassurance of the information obtained, a combination of multiple factors should be considered. For 6–8-mm lesions, the morphology, size, and interval growth of the nodule should be considered at the time of the management decision, even in the absence of cancer risk factors. The guidelines indicate that one follow-up examination should suffice in most cases and recommend optionally discontinuing the follow-up of well-defined solid nodules with a benign appearance at 12–18 months, as long as the nodule is measured accurately and its stability is unequivocal (4).

Scenario 3

For multiple solid pulmonary nodules that are 6 mm or larger, initial follow-up at 3–6 months is required, regardless of the risk factors. For low-risk patients, the guidelines suggest an optional additional follow-up at 18–24 months. Could 3-month stability of solid pulmonary nodules in a low-risk patient give false reassurance?

Pulmonary nodules incidentally discovered in low-risk patients are becoming increasingly common with the generalized use of CT. Data in another lung cancer screening study (31) indicate that up to 7% of individuals develop a new pulmonary nodule over time, and the likelihood of malignancy is higher in this specific population.

Although the recently updated guidelines for management of incidental nodules do not address those cases in which new pulmonary nodules smaller than 6 mm are found in low-risk patients with normal comparison thin-section CT findings, this scenario is common in clinical practice. The diagnostic considerations for patients with multiple solid pulmonary nodules are different from those for patients with solitary nodules. In the case of multiple solid nodules, metastases are the leading consideration, especially when the nodules are peripheral and basal in distribution. The volume doubling times of pulmonary metastases vary according to the biologic behavior of the original tumor and the size of the metastatic nodule, and have ranged from 20 to 160 days in some series (24,32). Metastatic lesions demonstrate growth within 3 months in the majority of cases (4).

The estimated risk of cancer in a low-risk patient with normal prior high-quality chest CT findings who is incidentally found after presentation to have new nodules smaller than 6 mm should be based on the results of individualized

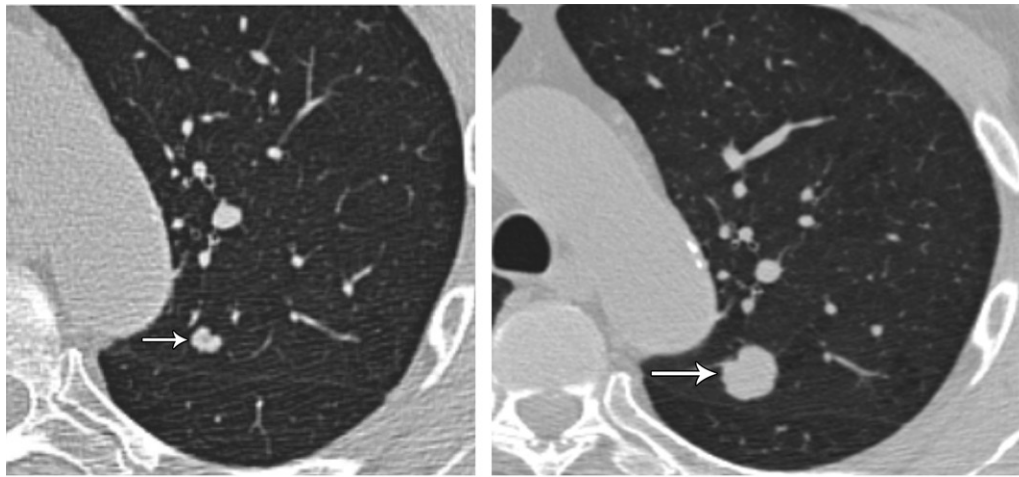


Figure 1. Solid pulmonary nodule smaller than 6 mm in a high-risk patient. **(a)** Axial nonenhanced chest CT image (lung window) of the left lung shows a 5-mm solid pulmonary nodule (arrow) with lobulated margins in the left upper lobe. **(b)** Axial nonenhanced chest CT image (lung window) at 12-month follow-up shows interval growth of the solid left upper lobe nodule (arrow), which now measures 13 mm and has persistent contour lobulation. Histopathologic analysis of the resected nodule revealed invasive adenocarcinoma.

patient examination and reassessment of risk factors and demographic information. This risk should be determined before the recommended guideline of no routine follow-up of nodules of this size (grade 2B recommendation: weak recommendation, moderate-quality evidence) is followed (4). In the absence of new risk factors, the likelihood that new small (<6-mm) nodules in a low-risk patient are benign is high, and these lesions most often represent postinfection granulomas or intrapulmonary lymph nodes (4).

In the case of low-risk patients with nodules 6 mm or larger, the guidelines recommend imaging follow-up. As described in clinical scenario 3, in a patient with stable solid nodules that are 6 mm or larger at initial 3-month follow-up, individual risk assessment findings and the patient's preferences should be considered to determine the next management step. According to the guidelines, optional follow-up is dependent on the estimated cancer risk for each patient (grade 1B recommendation: strong recommendation, moderate-quality evidence) (4), and the decision should be individualized. With the patient's environmental risk factors taken into account, the prevalence of granulomatous infections in the geographic area, number of nodules, and morphology of the dominant nodule will help define the most appropriate action. Note that the most suspicious (ie, dominant) nodule is not necessarily the largest lesion. The nodules' morphologic features (eg, margins and density), location, and growth rate, if available, should be taken into account to identify the dominant nodule that should be used to guide management (4,33).

Scenario 4

In the Fleischner Society guidelines, no routine follow-up is recommended for single GGNs smaller than 6 mm, regardless of the risk factors, with the added caveat that follow-up at 2 and 4 years should be considered for certain suspicious nodules. Which features make a GGN smaller than 6 mm suspicious for cancer?

In general, persistent pure GGNs that are 5 mm or smaller are believed to represent foci of atypical adenomatous hyperplasia, which is recognized as a preinvasive lung adenocarcinoma lesion (34). According to previous guidelines for the management of subsolid nodules, routine follow-up is not required for these lesions (5,12).

It is known that the growth rate of GGNs and subsolid nodules is slower than that of solid lesions, with a mean volume doubling time longer than 1100 days and a mean period of 3.6 years for the appearance of a solid component in one study (35) involving the assessment of GGNs smaller than 5 mm. The conservative management of GGNs smaller than 6 mm is justified owing to their high prevalence and known slow growth rate. However, it is known that almost 10% of these lesions demonstrate growth over time and 1% progress to malignancy (35).

Although in clinical practice the morphologic features of GGNs smaller than 6 mm are generally difficult to visualize owing to their small size and low density, the decision to perform further follow-up of these nodules should be based on the identification of suspicious features such as spiculation and fissure distortion (Fig 2). Owing to the slow growth rate, imaging follow-up on an annual basis is no longer indicated for GGNs

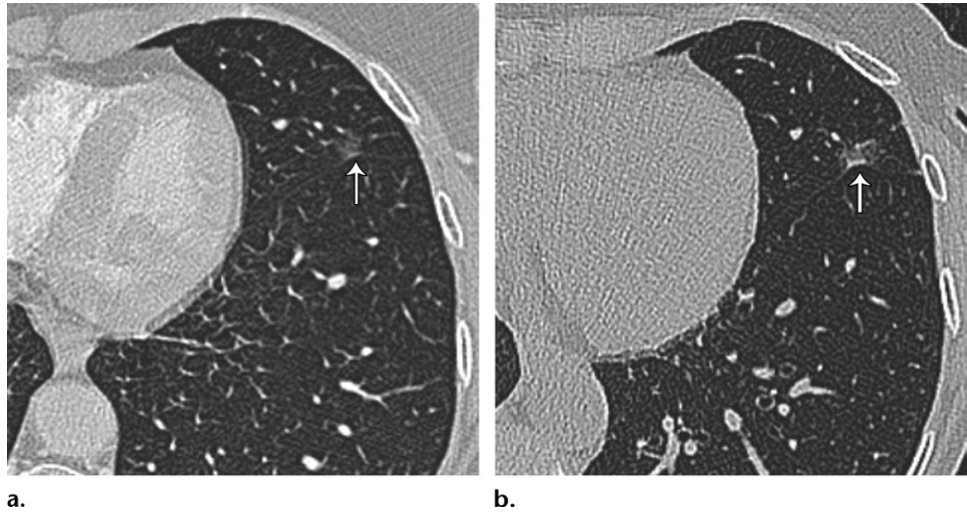


Figure 2. GGN smaller than 6 mm. **(a)** Axial contrast material–enhanced chest CT image (lung window) of the left lung shows a pure GGN in the lingula. There is retraction of the fissure (arrow), although it is subtle. Fissure retraction is a suspicious feature that warrants follow-up. **(b)** Axial nonenhanced chest CT image (lung window) obtained at 2-year follow-up shows an interval increase in the density of the nodule, with a new small solid perifissural component and progressive retraction of the fissure (arrow). These features are suspicious for malignancy.

smaller than 6 mm (12). For GGNs that are smaller than 6 mm and have suspicious features, an initial follow-up examination at 2 years and another follow-up at 4 years are indicated (4).

Scenario 5

The overall size of an 8-mm partly solid pulmonary nodule either is stable or has decreased, but the solid component has become enlarged and now measures 7 mm. What is the appropriate management protocol?

Small partly solid nodules are frequently due to transient infections and resolve spontaneously (36). The initial short-term follow-up indicated for partly solid nodules that are 6 mm or larger enables the clinician to accomplish various objectives: In the case of resolution, it provides reassurance to the patient and ordering provider; it facilitates the identification of occasionally rapidly enlarging lesions that require treatment; and if the nodule is stable, it enables confirmation of the persistence of a partly solid nodule to determine further management (12). Persistent partly solid nodules are more likely to be malignant (11,14).

Persistent partly solid nodules with a solid component smaller than 6 mm typically are adenocarcinomas in situ or minimally invasive adenocarcinomas. Both of these lesions have a 100% disease-specific survival rate when they are completely resected; thus, a conservative approach and management are justified (4,12,34).

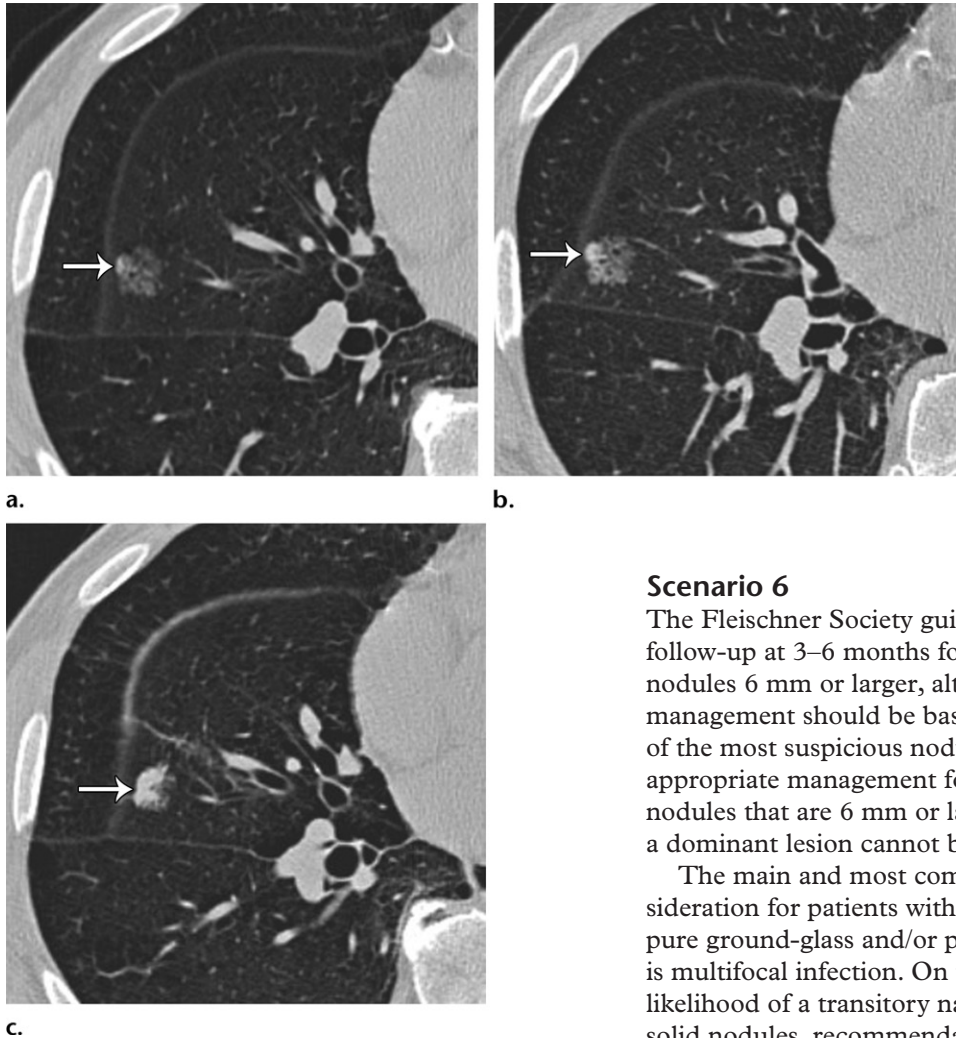
Some cancerous nodules demonstrate an initial decrease in size, which is a feature more frequently seen at assessment of subsolid lesion

growth patterns (37). Adenocarcinoma in situ has demonstrated nonlinear growth after an initial decrease in size or initial stability (38), which may be erroneously interpreted as benign behavior. The initial decrease in size is believed to be related to the development of fibrosis and microatelectasis (4,37) and is usually associated with an increase in attenuation. Awareness of this behavior during the assessment of subsolid nodules is essential to avoid misinterpretation. A decrease in size accompanied by an increase in density does not always indicate a benign lesion, and, thus, imaging surveillance is appropriate.

The solid component of a partly solid lesion is indicative of an invasive component. Progressive growth of the solid component beyond 5 mm increases the risk of invasiveness and metastasis (4,13,34). Thus, the more aggressive approach for partly solid lesions with a 6-mm or larger solid component is justified.

A partly solid lesion with a growing solid component that now measures 7 mm, as in the described scenario, represents a special challenge in terms of management (Fig 3). The interval growth of the solid component is highly suspicious for malignancy, although at this point, the size of the solid component limits management options. Although there is evidence that in experienced hands, a high degree of accuracy in the diagnosis of subsolid lesions can be achieved with fluoroscopically guided tissue-core lung biopsy (39), the results are less reliable for determining the specific cell type. The diagnostic accuracy of PET/CT in the differentiation of benign versus malignant

Figure 3. Partly solid nodule with increasing density of the solid component. **(a)** Axial nonenhanced chest CT image (lung window) of the right lung shows a partly solid nodule in the right middle lobe. The solid component (arrow) is very small, measuring less than 2 mm. **(b)** Axial nonenhanced chest CT image (lung window) obtained at 1-year follow-up shows stability in the overall size of the lesion but an increase in the size of the solid component (arrow), which now measures 3 mm. A few cystic spaces are more conspicuous than they were at initial manifestation. **(c)** Axial nonenhanced chest CT image (lung window) obtained 2 years after the image in **a** shows that the overall size of the right middle lobe nodule has decreased, but its solid component (arrow) has continued to increase and now measures 7 mm. Persistent partly solid nodules are highly suspicious for malignancy; the solid component specifically is suspicious for invasiveness.



solid nodules smaller than 10 mm is generally low (40). Although percutaneous biopsy of solid nodules smaller than 1.5 cm can be safely performed, it also has had lower accuracy (41). An individualized approach in which the patient's comorbidities and preferences are taken into account should be used to select the management option of local treatment, resection, or continued annual follow-up (grade 1B recommendation: strong recommendation, moderate-quality evidence) (4). Clinicians at some centers use definitive management (ie, resection or local radiation) for highly suspicious lesions in high-risk patients as part of their routine practice, even without a tissue sample-based diagnosis.

Scenario 6

The Fleischner Society guidelines recommend follow-up at 3–6 months for multiple subsolid nodules 6 mm or larger, although subsequent management should be based on the findings of the most suspicious nodule(s). What is the appropriate management for stable subsolid nodules that are 6 mm or larger in cases in which a dominant lesion cannot be identified?

The main and most common diagnostic consideration for patients with multiple subsolid (ie, pure ground-glass and/or partly solid) nodules is multifocal infection. On the basis of the high likelihood of a transitory nature of multiple subsolid nodules, recommendations for management have included an initial short-term follow-up examination to confirm persistency. According to the initial Fleischner Society recommendations for management of subsolid nodules published in 2009 and 2013 (11,12), the management of these lesions should be based on the number of nodules (solitary vs multiple) rather than the risk factors. This is mainly owing to the increasing incidence of adenocarcinoma among young persons and nonsmokers (12) and the lack of sufficient data to base management recommendations on smoking history. In the updated guidelines for managing incidental nodules, this classification is preserved, with recommendations based on size and density for single lesions (ie, single GGNs and single partly solid nodules) but similar follow-up recommendations based

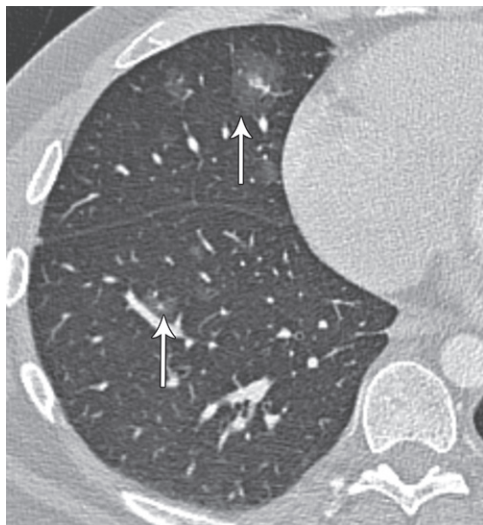

Figure 4. Multiple subsolid pulmonary nodules. Axial contrast-enhanced chest CT image (lung window) of the right lung shows multiple subsolid nodules (arrows) in the right middle and right lower lobes. All of these nodules are 6 mm or larger, but their solid component is small (<6 mm). In addition, all of these nodules were resolved at 6-month follow-up imaging (not shown), reflecting the transient nature of commonly encountered inflammatory or infectious subsolid nodules.

on nodule size (<6 mm vs \geq 6 mm) for multiple subsolid nodules.

Patients with multiple subsolid nodules are commonly encountered in clinical practice, and a conservative approach to management has been deemed appropriate (11). This conservative approach is based on the low likelihood of malignancy of small (<6-mm) lesions and proven slower growth rates compared with those of solid lesions (5,11,42). Owing to these considerations, the time frame for the initial imaging follow-up recommended in the updated guidelines has been increased to 3–6 months (from original initial 3-month follow-up) (4,12) to confirm persistence (Fig 4). The dominant, or most suspicious, nodule in the case of persistent lesions is used to determine further management, although the identification of this nodule is not always straightforward. The most suspicious nodule is not necessarily the largest lesion, so close attention to the morphologic features of the nodule is paramount.

The management of multiple subsolid 6-mm or larger pulmonary nodules that persist after the initial follow-up imaging examination at 3–6 months is based on the assumption that these lesions represent multiple primary adenocarcinomas (grade 1C recommendation: strong recommendation, low-quality or very-low-quality evidence) (4). Most patients with lung cancer who are found to have multiple subsolid nodules at the time of diagnosis have synchronous primary carcinomas

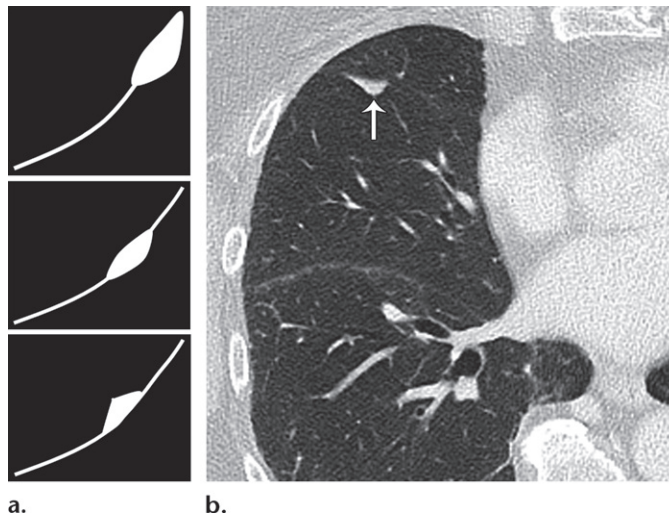


Figure 5. Perifissural nodule with the classic features of an intrapulmonary lymph node. (a) Illustrations depict the typical morphologic features of intrapulmonary lymph nodes. Association with the fissure and a triangular or lentiform morphology are characteristic features. (b) Axial non-enhanced chest CT image (lung window) of the right lung shows the typical appearance of an intrapulmonary lymph node (arrow), which is along the minor fissure in this case.

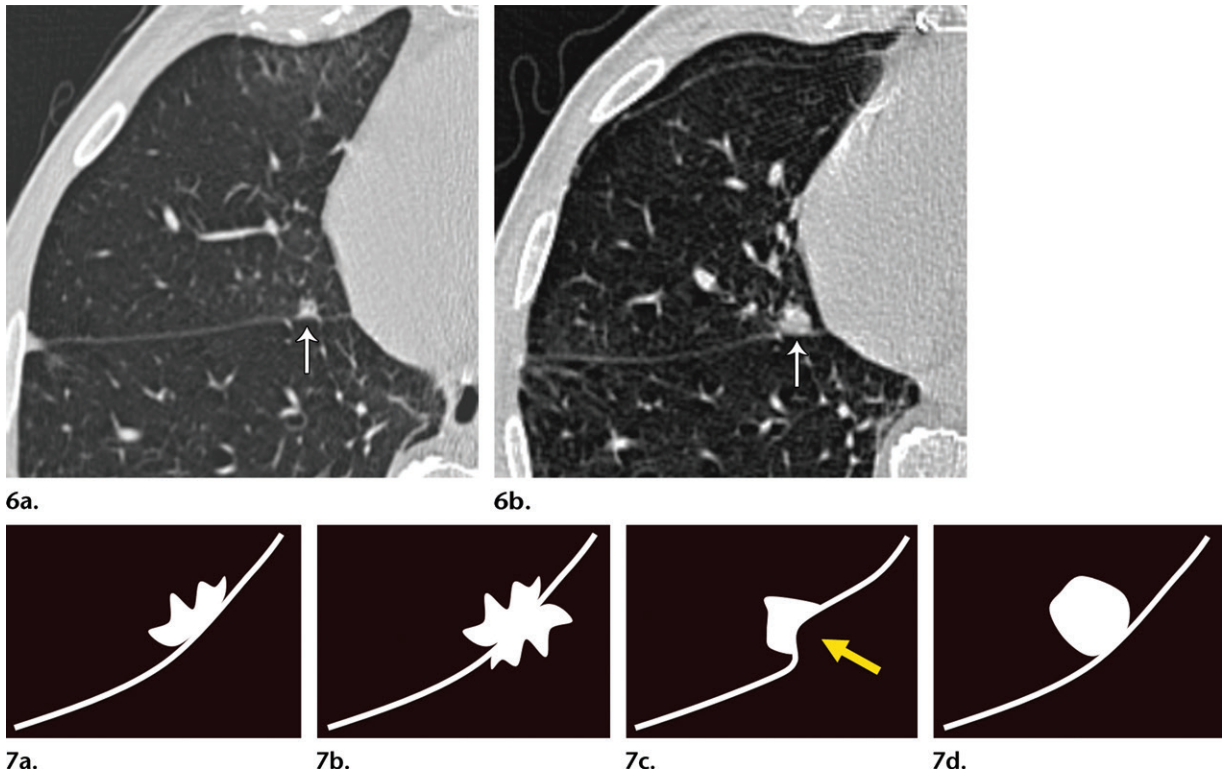
(43). As previously emphasized, interval growth of a solid component that is 6 mm or larger, spiculated margins, interval increase in density, and a new microcystic component are some of the most important features used to define the most suspicious lesion. However, the features that denote a dominant lesion are not clearly defined in the current guidelines (11,12,44).

Specific treatment strategies should be individualized, and further management options should be based on the features of the most suspicious subsolid nodule and other considerations such as patient and clinician preferences, similar to the approach for a subsolid lesion with a solid component larger than 6 mm in scenario 5. Conservative management of multiple stable 6-mm or larger subsolid nodules for which a dominant nodule is not identified should be based on careful assessment of the patient's relevant risk factors and demonstration of unequivocal lesion stability. If these lesions are stable at 3–6 months, it seems appropriate to follow the recommendation for single subsolid nodules with a solid component smaller than 6 mm: annual follow-up CT for a minimum of 5 years (4).

Scenario 7

A perifissural nodule has the typical morphologic characteristics of an intrapulmonary lymph node; however, it has increased in size from 5 to 8 mm within 6 months. Is further follow-up indicated?

Solid perifissural nodules are very common and are defined according to their juxtapleural



Figures 6, 7. (6) Perifissural nodule with suspicious features that warrant follow-up. (a) Axial nonenhanced chest CT image (lung window) of the right lung shows a 5-mm solid nodule (arrow) in the right middle lobe. The nodule has irregular contours and a juxtafissural location. (b) Axial nonenhanced chest CT image (lung window) obtained at 12-month follow-up shows interval growth of the nodule (arrow), with persistent contour irregularity. The lesion was found to represent a small invasive adenocarcinoma at resection. (7) Illustrations depict perifissural nodules with suspicious features: contour spiculation (a), fissural transgression (b), fissural distortion (arrow) (c), and a juxtafissural nodule not entirely associated with the fissure (d).

location. The prevalence of perifissural nodules can be as high as 20%, as has been observed in lung cancer screening populations (13,45). When perifissural nodules demonstrate a triangular or lentiform morphology, smooth contours, and sharp margins, they are known to represent intrapulmonary lymph nodes and are considered to be benign (13,46) (Fig 5). In large lung cancer screening populations (13,45), more than 15% of these nodules demonstrated interval growth, with growth rates in the range of those for malignant nodules. However, none of these nodules was cancer. In the general population, when the typical features of intrapulmonary lymph nodes are preserved in perifissural nodules, usually no follow-up CT examination is indicated. This guideline is applicable even if the average lesion dimension exceeds 6 mm and the nodules demonstrate interval growth (4).

Detailed assessment of the morphology of perifissural nodules is necessary to reliably determine management. A juxtapleural location is not always indicative of benignancy. Coronal and sagittal reconstructions are helpful for characterizing perifissural nodules and depicting the classic morphologic features and characteristic thin septal extension to the pleura (4). If a nodule

adjacent to the pleura or a fissure demonstrates a round morphology or contour irregularity and/or the adjacent fissure is abnormal (ie, retracted, bowed, or transgressed), follow-up CT at 6–12 months is indicated (4). These features are not reassuring in the case of an intrapulmonary lymph node, and stability should be demonstrated at interval imaging follow-up (Figs 6, 7).

Scenario 8

The incidence of lung cancer associated with cystic spaces is not insignificant, although there are no defined recommendations for cystic lesions in the current Fleischner Society guidelines. What suspicious features of a cystic lesion should prompt imaging follow-up?

The incidence of lung cancer associated with cystic spaces is variable and ranges from 1% to almost 4% (16,44). Pulmonary cysts are well-defined lesions surrounded by an epithelial wall of variable thickness (47). Benign cysts are characterized by thin (usually <2-mm) regular walls and can result from infection or trauma. In a retrospective study (44) involving 2954 patients with non-small cell lung carcinoma, cystic airspaces were seen in or adjacent to the primary lung cancer in approximately 1% of cases.

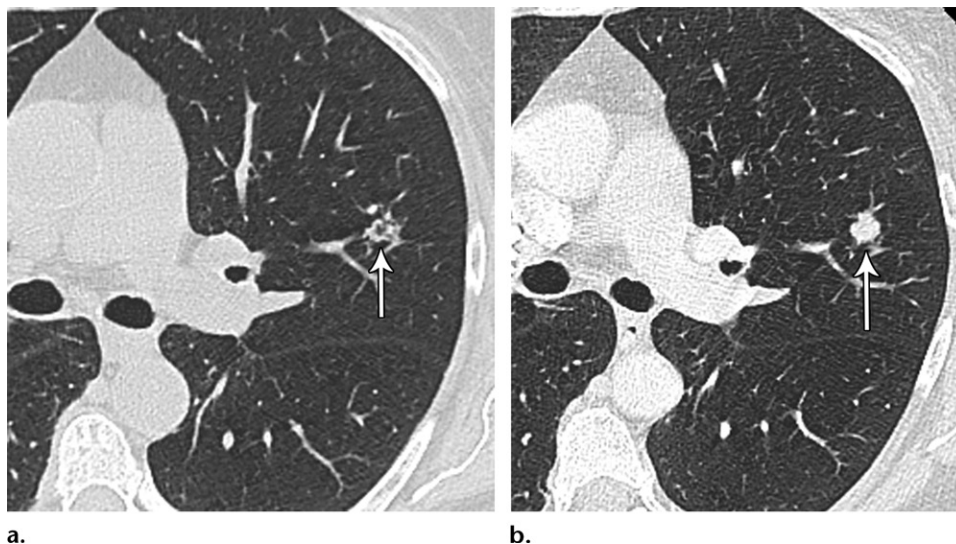


Figure 8. Solid pulmonary nodule with microcysts. (a) Axial contrast-enhanced CT image (lung window) of the left lung shows a solid nodule (arrow) that is larger than 8 mm and has irregular margins and central small spaces, representing microcysts, that are likely secondary to a check-valve mechanism. Despite its size, the lesion lacked a sufficient amount of solid component to warrant percutaneous biopsy. (b) Axial contrast-enhanced CT image (lung window) obtained at 6-month follow-up shows interval growth of the nodule (arrow), which is now entirely solid and has asymmetric contour lobulation. After resection, this lesion was found to represent a small invasive adenocarcinoma.

Cystic airspaces may appear in a preexisting solid or subsolid nodule and have been seen more frequently in association with histologically proven adenocarcinoma. Cystification (ie, appearance of new microcysts) of a nodule has been postulated to represent a check-valve mechanism that manifests as the tumor grows and obstructs small airways or to be due to tumor degeneration (44,48). The development of cystic areas in a nodule merits close attention at subsequent imaging examinations (Fig 8).

Tumor arising from the wall of a preexisting cyst is another common imaging appearance of cystic airspaces associated with lung cancer. Study investigators (48,49) have described a longitudinal process whereby a cystic lesion develops asymmetric wall thickening, which then transforms into an endophytic or exophytic mural nodule, with the cystic airspace subsequently replaced by soft tissue. These findings are indicative of lung cancer. Farooqi et al (48) reported a median period of 35 months for a cystic airspace to develop wall thickening or a mural nodule.

The suspicious features observed in cystic airspaces associated with primary lung cancer are new microcysts in a solid or subsolid nodule, or an endophytic mural nodule, exophytic mural nodule, and/or progressive or asymmetric wall thickening of a preexisting cystic lesion (Figs 9, 10). The recognition of these imaging findings in lesions associated with a cystic component should prompt imaging follow-up and/or a tissue sample-based diagnosis. The management decision should be made accord-

ing to the individual characteristics of the lesion and the patient's comorbidities and preferences.

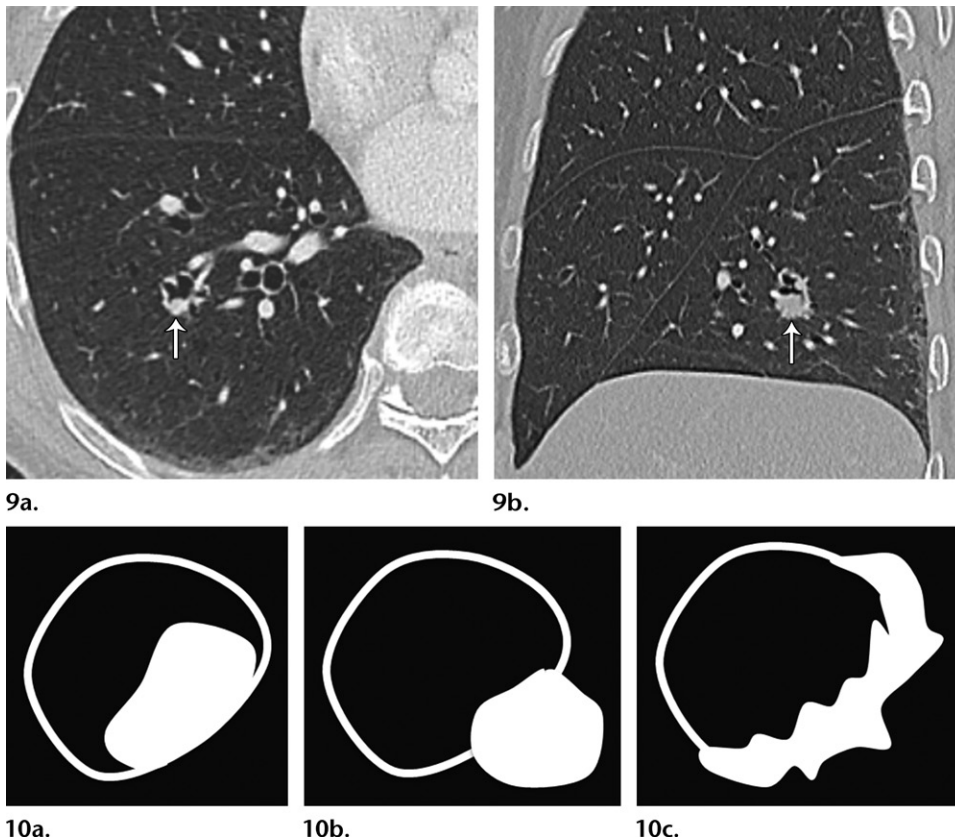
Conclusion

The 2017 updated Fleischner Society guidelines are intended to standardize the management of incidentally discovered pulmonary nodules and thereby reduce the number of unnecessary follow-up examinations. Current thinking regarding nodule management has been modified on the basis of data obtained from lung cancer screening programs, and the most recent guideline updates represent an attempt to address relevant clinical factors in the management process. While allowing radiologists, treating physicians, and patients greater discretion in management decisions, the recent modifications demand a better understanding of the factors that influence lung cancer risk and rely on greater capability to recognize the morphology of suspicious nodules. To facilitate appropriate use of the updated Fleischner guidelines, we offer clarifications for specific scenarios that are commonly encountered in clinical practice.

Acknowledgment.—We acknowledge Heber MacMahon, MB, BCh, for his time and input in the preparation of this article.

References

1. MacMahon H, Austin JHM, Gamsu G, et al. Guidelines for management of small pulmonary nodules detected on CT scans: a statement from the Fleischner Society. *Radiology* 2005;237(2):395–400.
2. Guidelines for management of small pulmonary nodules detected on CT scans: a statement of the Fleischner Society—overview of attention for article published in *Radiology*, January 2005.



Figures 9, 10. (9) Cystic lung lesion with suspicious features. (a) Axial contrast-enhanced CT image (lung window) of the right lung shows a cystic lesion in the right lower lobe. There is asymmetric wall thickening and an endophytic mural nodule (arrow), features that are highly suspicious for malignancy. (b) Sagittal contrast-enhanced CT image (lung window) better shows the endophytic nodule (arrow) in the inferior wall of the suspicious right lower lobe cystic lesion. (10) Illustrations depict the suspicious features of cystic lesions: endophytic nodule (a), exophytic nodule (b), and asymmetric wall thickening (c).

RSNA Article Metrics website. <https://rsna.altmetric.com/details/985790>. Accessed January 3, 2018.

- Eisenberg RL, Bankier AA, Boiselle PM. Compliance with Fleischner Society guidelines for management of small lung nodules: a survey of 834 radiologists. *Radiology* 2010;255(1):218–224.
- MacMahon H, Naidich DP, Goo JM, et al. Guidelines for management of incidental pulmonary nodules detected on CT images: from the Fleischner Society 2017. *Radiology* 2017;284(1):228–243.
- Gould MK, Donington J, Lynch WR, et al. Evaluation of individuals with pulmonary nodules: when is it lung cancer? diagnosis and management of lung cancer, 3rd ed: American College of Chest Physicians evidence-based clinical practice guidelines. *Chest* 2013;143(5 suppl):e93S–e120S.
- Lacson R, Prevedello LM, Andriole KP, et al. Factors associated with radiologists' adherence to Fleischner Society guidelines for management of pulmonary nodules. *J Am Coll Radiol* 2012;9(7):468–473.
- Esmaili A, Munden RF, Mohammed TL. Small pulmonary nodule management: a survey of the members of the Society of Thoracic Radiology with comparison to the Fleischner Society guidelines. *J Thorac Imaging* 2011;26(1):27–31.
- Tanner NT, Porter A, Gould MK, Li XJ, Vachani A, Silvestri GA. Physician assessment of pretest probability of malignancy and adherence with guidelines for pulmonary nodule evaluation. *Chest* 2017;152(2):263–270.
- Eisenberg RL; Fleischner Society. Ways to improve radiologists' adherence to Fleischner Society guidelines for management of pulmonary nodules. *J Am Coll Radiol* 2013;10(6):439–441.
- MacMahon H. Compliance with Fleischner Society guidelines for management of lung nodules: lessons and opportunities. *Radiology* 2010;255(1):14–15.
- Godoy MCB, Naidich DP. Subsolid pulmonary nodules and the spectrum of peripheral adenocarcinomas of the lung: recommended interim guidelines for assessment and management. *Radiology* 2009;253(3):606–622.
- Naidich DP, Bankier AA, MacMahon H, et al. Recommendations for the management of subsolid pulmonary nodules detected at CT: a statement from the Fleischner Society. *Radiology* 2013;266(1):304–317.
- McWilliams A, Tammemagi MC, Mayo JR, et al. Probability of cancer in pulmonary nodules detected on first screening CT. *N Engl J Med* 2013;369(10):910–919.
- Horeweg N, van Rosmalen J, Heuvelmans MA, et al. Lung cancer probability in patients with CT-detected pulmonary nodules: a prespecified analysis of data from the NELSON trial of low-dose CT screening. *Lancet Oncol* 2014;15(12):1332–1341.
- Bankier AA, MacMahon H, Goo JM, Rubin GD, Schaefer-Prokop CM, Naidich DP. Recommendations for measuring pulmonary nodules at CT: a statement from the Fleischner Society. *Radiology* 2017;285(2):584–600.
- Henschke CI, McCauley DI, Yankelevitz DF, et al. Early Lung Cancer Action Project: overall design and findings from baseline screening. *Lancet* 1999;354(9173):99–105.
- Wahidi MM, Govert JA, Goudar RK, Gould MK, McCrory DC. Evidence for the treatment of patients with pulmonary nodules: when is it lung cancer? ACCP evidence-based clinical practice guidelines (2nd edition). *Chest* 2007;132(3 suppl):94S–107S.
- Hanahan D, Weinberg RA. Hallmarks of cancer: the next generation. *Cell* 2011;144(5):646–674.
- White MC, Holman DM, Boehm JE, Peipins LA, Grossman M, Henley SJ. Age and cancer risk: a potentially modifiable relationship. *Am J Prev Med* 2014;46(3 suppl 1):S7–S15.
- Hong JC, Salama JK. The expanding role of stereotactic body radiation therapy in oligometastatic solid tumors: what do we know and where are we going? *Cancer Treat Rev* 2017;52:22–32.
- Davidson RS, Nwogu CE, Brentjens MJ, Anderson TM. The surgical management of pulmonary metastasis: current concepts. *Surg Oncol* 2001;10(1-2):35–42.

22. Davis SD. CT evaluation for pulmonary metastases in patients with extrathoracic malignancy. *Radiology* 1991;180(1):1–12.
23. Chojniak R, Younes RN. Pulmonary metastases tumor doubling time: assessment by computed tomography. *Am J Clin Oncol* 2003;26(4):374–377.
24. Kim EY, Lee JI, Sung YM, et al. Pulmonary metastases from colorectal cancer: imaging findings and growth rates at follow-up CT. *Clin Imaging* 2012;36(1):14–18.
25. Heitkamp DE, Mohammed TL, Kirsch J, et al. ACR appropriateness criteria® acute respiratory illness in immunocompromised patients. *J Am Coll Radiol* 2012;9(3):164–169.
26. Franquet T. High-resolution computed tomography (HRCT) of lung infections in non-AIDS immunocompromised patients. *Eur Radiol* 2006;16(3):707–718.
27. Moyer VA; U.S. Preventive Services Task Force. Screening for lung cancer: U.S. Preventive Services Task Force recommendation statement. *Ann Intern Med* 2014;160(5):330–338.
28. Lung CT screening reporting and data system. American College of Radiology website. <https://www.acr.org/Quality-Safety/Resources/LungRADS>. Published 2014. Accessed January 18, 2018.
29. Zhao YR, van Ooijen PM, Dorrius MD, et al. Comparison of three software systems for semi-automatic volumetry of pulmonary nodules on baseline and follow-up CT examinations. *Acta Radiol* 2014;55(6):691–698.
30. Callister MEJ, Baldwin DR, Akram AR, et al. British Thoracic Society guidelines for the investigation and management of pulmonary nodules. *Thorax* 2015;70(suppl 2):ii1–ii54. [Published correction appears in *Thorax* 2015;70(12):1188.]
31. Gould MK, Fletcher J, Iannettoni MD, et al. Evaluation of patients with pulmonary nodules: when is it lung cancer? ACCP evidence-based clinical practice guidelines (2nd edition). *Chest* 2007;132(3 suppl):108S–130S.
32. Plesnicar S, Klanjscek G, Modic S. Actual volume doubling time values for pulmonary metastases from soft tissue sarcomas. *Cancer Lett* 1978;4(6):311–316.
33. Erasmus JJ, Connolly JE, McAdams HP, Roggli VL. Solitary pulmonary nodules. I. Morphologic evaluation for differentiation of benign and malignant lesions. *RadioGraphics* 2000;20(1):43–58.
34. Travis WD, Brambilla E, Noguchi M, et al. International Association for the Study of Lung Cancer/American Thoracic Society/European Respiratory Society: international multidisciplinary classification of lung adenocarcinoma. *J Thorac Oncol* 2011;6(2):244–285.
35. Kakinuma R, Muramatsu Y, Kusumoto M, et al. Solitary pure ground-glass nodules 5 mm or smaller: frequency of growth. *Radiology* 2015;276(3):873–882.
36. Henschke CI, Shaham D, Yankelevitz DF, Altorki NK. CT screening for lung cancer: past and ongoing studies. *Semin Thorac Cardiovasc Surg* 2005;17(2):99–106.
37. Lindell RM, Hartman TE, Swensen SJ, Jett JR, Midthun DE, Mandrekar JN. 5-year lung cancer screening experience: growth curves of 18 lung cancers compared to histologic type, CT attenuation, stage, survival, and size. *Chest* 2009;136(6):1586–1595.
38. Lindell RM, Hartman TE, Swensen SJ, et al. Five-year lung cancer screening experience: CT appearance, growth rate, location, and histologic features of 61 lung cancers. *Radiology* 2007;242(2):555–562.
39. Yamagami T, Yoshimatsu R, Miura H, et al. Diagnostic performance of percutaneous lung biopsy using automated biopsy needles under CT-fluoroscopic guidance for ground-glass opacity lesions. *Br J Radiol* 2013;86(1022):20120447.
40. Tsunezuka Y, Shimizu Y, Tanaka N, Takayanagi T, Kawano M. Positron emission tomography in relation to Noguchi's classification for diagnosis of peripheral non-small-cell lung cancer 2 cm or less in size. *World J Surg* 2007;31(2):314–317.
41. Kothary N, Lock L, Sze DY, Hofmann LV. Computed tomography-guided percutaneous needle biopsy of pulmonary nodules: impact of nodule size on diagnostic accuracy. *Clin Lung Cancer* 2009;10(5):360–363.
42. Lee KH, Goo JM, Park SJ, et al. Correlation between the size of the solid component on thin-section CT and the invasive component on pathology in small lung adenocarcinomas manifesting as ground-glass nodules. *J Thorac Oncol* 2014;9(1):74–82.
43. Nakata M, Sawada S, Yamashita M, et al. Surgical treatments for multiple primary adenocarcinoma of the lung. *Ann Thorac Surg* 2004;78(4):1194–1199.
44. Fintelmann FJ, Brinkmann JK, Jeck WR, et al. Lung cancers associated with cystic airspaces: natural history, pathologic correlation, and mutational analysis. *J Thorac Imaging* 2017;32(3):176–188.
45. de Hoop B, van Ginneken B, Gietema H, Prokop M. Pulmonary perifissural nodules on CT scans: rapid growth is not a predictor of malignancy. *Radiology* 2012;265(2):611–616.
46. Walter JE, Heuvelmans MA, de Jong PA, et al. Occurrence and lung cancer probability of new solid nodules at incidence screening with low-dose CT: analysis of data from the randomised, controlled NELSON trial. *Lancet Oncol* 2016;17(7):907–916.
47. Hansell DM, Bankier AA, MacMahon H, McLoud TC, Müller NL, Remy J. Fleischner Society: glossary of terms for thoracic imaging. *Radiology* 2008;246(3):697–722.
48. Farooqi AO, Cham M, Zhang L, et al. Lung cancer associated with cystic airspaces. *AJR Am J Roentgenol* 2012;199(4):781–786.
49. Mascalchi M, Attinà D, Bertelli E, et al. Lung cancer associated with cystic airspaces. *J Comput Assist Tomogr* 2015;39(1):102–108.