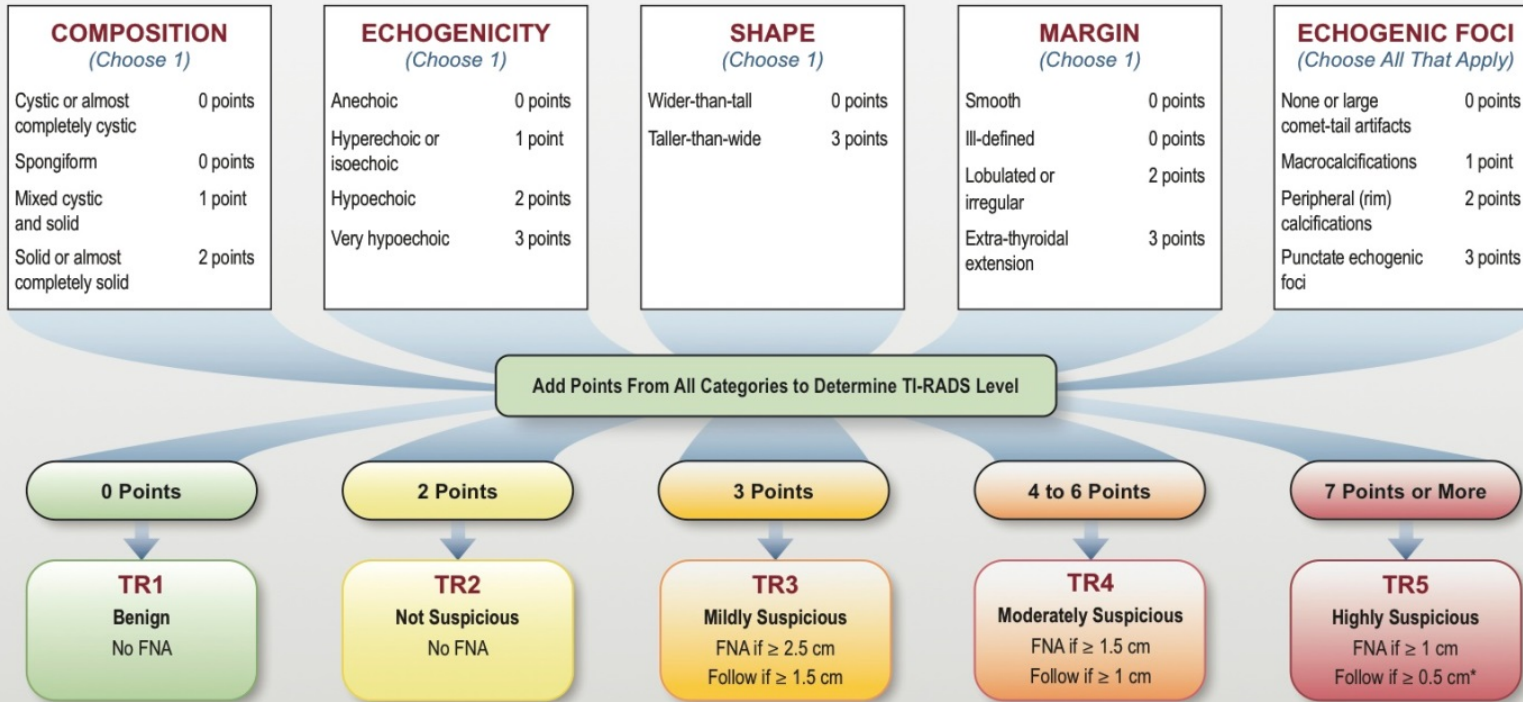


ACR TI-RADS



COMPOSITION	ECHOGENICITY	SHAPE	MARGIN	ECHOGENIC FOCI
<p><i>Spongiform</i>: Composed predominantly (>50%) of small cystic spaces. Do not add further points for other categories.</p> <p><i>Mixed cystic and solid</i>: Assign points for predominant solid component.</p> <p>Assign 2 points if composition cannot be determined because of calcification.</p>	<p><i>Anechoic</i>: Applies to cystic or almost completely cystic nodules.</p> <p><i>Hyperechoic/isoechoic/hypoechoic</i>: Compared to adjacent parenchyma.</p> <p><i>Very hypoechoic</i>: More hypoechoic than strap muscles.</p> <p>Assign 1 point if echogenicity cannot be determined.</p>	<p><i>Taller-than-wide</i>: Should be assessed on a transverse image with measurements parallel to sound beam for height and perpendicular to sound beam for width.</p> <p>This can usually be assessed by visual inspection.</p>	<p><i>Lobulated</i>: Protrusions into adjacent tissue.</p> <p><i>Irregular</i>: Jagged, spiculated, or sharp angles.</p> <p><i>Extra-thyroidal extension</i>: Obvious invasion = malignancy.</p> <p>Assign 0 points if margin cannot be determined.</p>	<p><i>Large comet-tail artifacts</i>: V-shaped, >1 mm, in cystic components.</p> <p><i>Macrocalcifications</i>: Cause acoustic shadowing.</p> <p><i>Peripheral</i>: Complete or incomplete along margin.</p> <p><i>Punctate echogenic foci</i>: May have small comet-tail artifacts.</p>

*Refer to discussion of papillary microcarcinomas for 5-9 mm TR5 nodules.